

INFLUENCES OF DYSFUNCTIONAL RESPIRATORY MECHANICS ON OROFACIAL PAIN

Ronald J. Hruska, Jr, MPA, PT

The influence of faulty breathing patterns on normal mandibular rest position and cervical cranial alignment has been documented.^{44, 70} Increased freeway space, compression of the temporomandibular and suboccipital joints, increased posterior intercuspation, and increased cervical lordosis as a result of posterior cranial rotation or forward head posturing can lead to upper and lower quadrant postural adaptations, craniofacial alterations, and pain.^{35, 43} Overuse of both primary and secondary muscles of respiration often contributes to craniofacial pain and associated symptoms of cervical origin, largely because of their mechanical relation to the cervical and suboccipital region and their influences on forward head posturing.

Overuse and reflex guarding of the anterior musculature of the neck is often associated with acute traumatic events such as whiplash.⁴² Hyperactivity of the scalenes, longus colli, sternocleidomastoids (SCMs), levator scapula, upper trapezius, and hyoid musculature as a result of nontraumatic respiratory mechanical dysfunction, however, may also result in forward inclination of the head and concomitant temporomandibular disorders (TMD) and craniofacial pain (CFP). The influence of specific dysfunctional respiratory mechanics on TMD as outlined by existing literature is limited. Of more concern is the scanty existence of documentation on specific treatment for inspiratory muscle fatigue, dyspnea, hyperinflation, paradoxical breathing, diaphragm hypertonicity, or dys-synchronous respiration as a result of improper or unbalanced tension between the diaphragm and the obliques.

From the Department of Physical Therapy and Rehabilitation Services, St. Elizabeth Community Health Center, Lincoln, Nebraska

DENTAL CLINICS OF NORTH AMERICA

This article reviews the anatomic issues of respiration and the mechanics of the thorax and their influences of forward head posture and TMD. The role of strength training, diaphragmatic breathing, and positioning is presented as it relates to TMD or CFP.

RESPIRATORY ANATOMIC CONCEPTS

Respiratory skeletal muscles are composed of both inspiratory and expiratory muscles that depend on each other for ventilation to occur. They each have an inactive and an active state that pumps air in and out of the gas exchange portion of the thoracic cage. To understand the mechanics of thoracic ventilation, one must have a basic appreciation for respiratory muscle function.

Diaphragm

The most important inspiratory muscle is the dome-shaped diaphragm that separates the thorax from the abdominal cavity. It possesses a central noncontractile tendinous portion from which radially oriented muscle fibers descend in an outward manner to insert in the circumferential caudal limits of the rib cage.^{3, 17, 38} The costal diaphragm inserts in the posterior portion of the xiphoid process and in the inner surface of the lower six ribs and costal cartilages. The crural muscle fiber arises from the arcuate ligament and inserts into the upper three lumbar bodies on the right and two on the left.²⁰ In individuals with situs solitus and levocardia, the left hemidiaphragm is always at a lower position than the right diaphragm. This observation is relevant to all ages and is believed to exist because of the liver's shape and support of the right hemidiaphragm's form.⁵⁹ Others believe that it is the cardiac mass and not the liver that determines the posture of the hemidiaphragms.⁵⁹ It is important to recognize that there is a certain consistent characteristic position of each hemidiaphragm that, in the author's opinion, does influence the mechanics of the thorax and postural demands placed on the low back and neck.

Another unique feature of this broad muscle is that each hemidiaphragm has a unilateral, contralateral cortical representation.⁴⁸ The motor neurons that innervate the diaphragm originate at C3 to C5 and travel the phrenic nerve.⁶ Because the proprioceptor receptors of the diaphragm are sparse, most of the diaphragm's ability to compensate for increased demands comes from the Golgi tendon organs or its intrinsic contractile properties, similar to the antigravitational or postural muscle.²²

The diaphragm's mechanical action depends on its relationship and anatomic arrangement with the rib cage.^{26, 41} The cylindrical aspect of the diaphragm that opposes the lower rib cage constitutes the zone of apposition. The area of apposition of diaphragm to rib cage makes up a substantial but variable fraction of the total surface area of the rib cage. It accounts for more than one half of the total surface at residual volume and decreases to zero at total lung capacity.⁵¹ During quiet breathing in the upright posture, it represents one fourth to one third of the total surface area of the rib cage.⁵¹ The zone of apposition has anatomic importance because it is controlled by the abdominal and oblique muscles and directs diaphragmatic tension. Accessory respiratory muscle overuse is also influenced by diaphragmatic position and changes in the zone of apposition.

On contraction, the diaphragm leans against the abdominal content. The

viscera, the abdominal organs, and ultimately the pelvic floor serve as a fulcrum while the rib cage lifts and expands.^{3, 26, 41} If the abdominal content offers no resistance, secondary to weak obliques, the diaphragm would only displace itself downward with a smaller increase in abdominal pressure and a concomitant decrease in its lifting and expanding action on the rib cage. When the zone of apposition increases, the abdominal pressure increases with concomitant expansion of the lower rib cage.³

It is also argued that diaphragmatic volume displacements cause equal displacements of abdominal contents.⁵² During quiet inspiration, it is estimated that more than half of the total rib cage volume goes into abdominal expansion. The outward displacement of the anterolateral abdominal wall constitutes the other half of the diaphragmatic displacement.⁵² Without good oblique-abdominal tone, more than one half of the total rib cage volume would go into abdominal expansion. A subsequent decrease in the zone of apposition would change anatomic alignment of anterior cervical muscle and fascia as a result of forward, outward, and upward displacement of the anterior rib cage. The gravitational pull on the accessory respiratory muscle secondary to rib cage and abdominal wall anterolateral displacement contribute to the development of a forward head and posterior cranial rotation.³¹

Other Inspiratory Muscle Considerations

The diaphragm is responsible for 70% to 80% of the work of breathing under quiet breathing conditions. The other 30% of inspiratory work is performed by the scalenes, sternocleidomastoids, external intercostals, and parasternal intercostals.⁴⁰

The scalene muscles lift and expand the rib cage during inspiration and are active during every inspiratory effort and are therefore considered a primary muscle, not an accessory muscle.¹⁶ The ribs are also lifted by the parasternal intercostals. Both of these lifting muscles can draw the head and neck forward during high levels of inspiratory demand and can create additional stabilizing demand from the neck because they increase the anterior-posterior dimension of the rib cage.^{18, 60} Tonic activity of these inspiratory muscles plays an important role in adjusting and maintaining posture.⁶⁵ It would stand to reason that phasic activity can therefore contribute to postural discord and a forward head posture in an upright position.

The inspiratory action of the parasternal and scalene muscle groups on the upper thorax is to counteract the expiratory action of the diaphragm on the upper rib cage.^{18, 40} As the diaphragm descends, it decreases the pleural pressure necessary for inspiration. The decrease in pleural pressure is greatest in the cephalad regions around the apex of the lung.⁶⁰ If unopposed by the contraction of the parasternals and scalenes, the upper rib cage moves inward in a direction that is reflective of expiration. Thus, a forward head posture could lead to unopposed diaphragmatic inspiration, decreased pleural pressure, and patterns of dysfunctional breathing.

The sternocleidomastoid muscles, because of their insertion onto the mastoid process and occipital bone, probably have the most significant influence on posterior cranial rotation and forward head posture. As an inspiratory muscle group, they enhance the *pump handle* elevation of the first rib and the sternum. They remain active at high levels of ventilatory demands or at high lung volumes such as the case of hyperinflation.¹⁴

Although the pectoralis major, pectoralis minor, latissimus dorsi, serratus

anterior, and trapezius are not typically considered accessory respiratory muscles, the author believes they become respiratory oriented rather than posturally oriented in the dysfunctional dyssynchronous or paradoxical breather. All of these muscles influence the rib cage and an extrathoracic anchoring point.^{6, 8} Because of their insertions, they assist with inspiration and the pulling of the rib cage up and out.³ Dyspneic patients assume a forward head posture to increase the resting diaphragmatic length, the zone of opposition, and contractibility.⁶⁶ Patients who have forward head postures lean forward and often rest their arms on a hard surface to anchor these extrathoracic muscles. This position increases their length and assists in their ability to generate greater pull or lift of the ribs.

Expiratory Muscle

The rectus abdominis, external and internal obliques, transverse abdominals, interosseous part of the external intercostals, and transverse thoracic muscles are all expiratory muscles, yet can be considered accessory in nature because of their elastic recoil of the lungs in the asymptomatic individual.^{19, 24, 31, 60} These muscles, especially the obliques, are responsible for formation of a fulcrum for diaphragmatic contraction during inspiration, increased lung volume, lengthening of the diaphragm at rest and end expiration, and increased zone of apposition.^{3, 53} They preserve active trunk rotation, shape and stability of the rib cage, abdominal pressure, and favorable diaphragmatic length tension curve.^{17, 52} Because the radius of the curvature of the diaphragm is also decreased, the transdiaphragmatic pressure of a diaphragmatic contraction increases.¹³

Weakness of the oblique muscles allows for excessive shortening of the diaphragm, decreased descent of the diaphragmatic dome, and strain of lumbo-costal ligaments and crura. Over time the length tension curve is decreased, and the diaphragm becomes postural in orientation at its posterior linkage with the quadratus lumborum and psoas musculature and fascia.³¹ It can be argued that the abdominal muscle is eccentric in nature during inspiration because of the need to maintain a zone of apposition, length-to-tension ratios between the diaphragm and abdominals, and stability and support during trunk rotation. Abdominal weakness, as outlined in Table 1, can have a subtle yet impacting effect on posture and TMD.

MECHANICS OF THE THORAX

Breathing and its mechanics involve displacement of the abdominal wall or the rib cage.^{27, 34, 68} The total volume change of the thoracic cavity equals the sum of the volumes displaced by the abdominal wall and rib cage, which also equals the volume change of the lung. Forces developed by the inspiratory muscles act on the abdomen and rib cage to displace them and to increase lung volume.⁶³

The diaphragm has two components, costal and crural, which function differently.²⁰ As the costal aspect of the diaphragm contracts, the dome displaces the abdominal viscera downward. If the obliques have sufficient length tension, the viscera and the obliques resist being displaced, and the costal fibers of the diaphragm develop a force on the rib cage, which lifts it. Costal diaphragmatic contraction displaces both the rib cage and the abdomen while inflating the lung.⁶³ Contraction of the crural aspect of the diaphragm displaces only the abdomen while it inflates the lungs, because it attaches only to the lumbar

Table 1. MAJOR EFFECTS OF PROLONGED ABDOMINAL WEAKNESS ON TEMPOROMANDIBULAR DISORDERS

Decreases intra-abdominal pressure
Decreases zone of apposition (seen more often with left hemidiaphragm involvement)
Decreases length tension advantage of the diaphragm
Promotes asymmetry of rib cage with torsional influences on alignment of spine and ribs
Promotes passive rib flares
Decreases lung and intercostal elasticity
Promotes hyperinflation of lungs secondary to hemidiaphragmatic flattening (usually on the left)
Facilitates overuse and overdevelopment of accessory inspiratory muscle
Promotes dyssynchronous or asynchronous breathing patterns
Promotes forward head postural compensation
Alters suboccipital proprioceptive input
Increases cervical, cranial, and mandibular joint compression
Alters posterior occlusal contact
Promotes mandibular reposition
Facilitates masticatory hyperactivity, temporomandibular joint hypomobility, and craniofacial pain

spine.²⁰ The two components of the diaphragm have different segmental innervation, different actions, and different embryologic and evolutionary origins.^{36, 64}

Therefore, it is important to respect the diaphragm as two separate muscles, crural and costal, and as two hemispheres, left and right. Length-to-tension ratios, tone, coordination of timing between the upper and lower diaphragm and between the left and right hemispheres, and passive or active properties of the thorax can all influence the external intercostal muscles or accessory muscles and ultimately the demand on the head and neck for structural anchoring.

Length-Tension Relationships

To preserve lung tidal volume and proper thoracic symmetry, both the rib cage and the abdominal expiratory muscles must work together to maintain or restore diaphragmatic length and length tension.⁶¹ Length tension can be described as the tension exerted by a skeletal muscle fiber as a result of the length at which it contracts. Skeletal muscle generates force optimally at its usual resting length. As it shortens, it generates force less effectively, until at a length between 40% to 65% of resting length, the active force generated falls to zero.

The maximal negative pressure that can be generated by the inspiratory muscles is greatest at residual volume and decreases as a function of lung volume, becoming zero at total lung capacity. Maximum positive pressures exerted by the expiratory muscles are greatest at large lung volumes and decrease as lung volume decreases, becoming zero at residual volume.^{58, 65} Inspiratory muscles would be maximally stretched at residual volume and maximally shortened at total lung capacity. The opposite would be true of the expiratory muscles.⁶⁵ Mechanical effectiveness of the inspiratory intercostal muscles is reduced, also, at large lung volumes, at which there is a more horizontal position of the ribs and a greater angle between inspiratory intercostals and subjacent

ribs. Less transdiaphragmatic pressure is likely with a larger diaphragm radius or at larger lung volumes (hyperinflation).

Therefore, abdominal muscle resting tension complements the inspiratory action of the diaphragm by facilitating an increase in pressure in the abdominal compartment rather than outward protrusion of the abdomen during diaphragmatic contraction.^{18, 60} The zone of apposition and dome shape of the diaphragm are maintained during inspiration by abdominal or internal oblique muscle resting tension supporting the abdominal viscera up against the diaphragm.⁵²

Respiratory Muscle Tone

Muscle tone is important for any of the skeletal muscles of the trunk. The trunk muscles are postural in nature. In other words, they are responsible for gravitational support and rotational demands. To respond efficiently to these upright demands, the agonistic and antagonistic trunk muscle at rest remains balanced through development of tone. Antagonistic tone, for example, of the internal obliques maximized the concentric contraction of the diaphragm and restores the diaphragm's postcontraction length.

Respiratory muscle manifests in both phasic and tonic activity.⁶⁵ Phasic respiratory activity reflects either inspiration or expiration. Tonic respiratory activity reflects activity that is continuous in both inspiration and expiration phases. Electromyography testing demonstrates tonic activity in intercostal and cervical accessory muscles and in the diaphragm during abdominal mass loading. Abdominal muscle tonic activity is generally present during standing and somewhat less during sitting. Little activity has been noted in supine.⁶⁵ Evidence shows that patients with severe chronic obstructive lung disease have significant tonic activity, generally greater than normal, in the cervical accessory and abdominal muscle.²¹ Another study has demonstrated increased tonic activity in both the diaphragm and the intercostal muscles in acute episodes of asthma.⁴⁷

It can be theorized that increased tonic tone of the cervical accessory muscles and the diaphragm occurs as a result of decreased antagonistic tonic activity of the abdominal musculature. This is often the case seen in the clinic with patients who reflect forward head postures and temporomandibular dysfunction. Large lung volume or hyperinflation, usually seen more so on the left chest, suggests hypertonicity, or possible spasticity of one or both hemidiaphragms. Clinically, the author has found hemidiaphragm hypertonicity complementing ipsilateral abdominal and oblique muscle weakness. This pattern is usually seen involving the left hemidiaphragm with contralateral cervical symptoms and dysfunction on the right.³¹

Another study outlines the relationship of diaphragmatic spasm or hypertonicity to noncardiac sources of chest pain and dyspnea.⁷¹ Patients with temporomandibular dysfunction often report accompanying difficulty with episodes of respiratory difficulty and tightness of substernal or chest area. Other associated symptoms may include apprehension, anxiety, sweating, and pallor. The author has also seen a number of patients with temporomandibular dysfunction express and locate pain in or near the right hypochondrial region. Fluoroscopy demonstrates that the pattern of respiration in these types of patients reflects failure of the diaphragm to rise in relaxation to its former level with each successful expiration.⁷¹ This dysfunctional pattern also seemed to be enhanced with quick, deep inspiratory movements. Thus, each breath made the lungs more inflated and the diaphragm tighter until ventilatory capacity was exceeded with the

diaphragm apparently tightly contracted. This flattened diaphragm usually involves the left hemidiaphragm more than the right.³¹

Pain from diaphragmatic spasm or hypertonicity is relayed by both the phrenic nerve that enters the spinal cord at the third, fourth, and fifth cervical segments and the thoracic segments. The location of diaphragmatic pain may be similar to that of angina pectoris or may be comparable to *stitch in the side* discomfort that frequently occurs in runners. The mechanism of this pain appears to be that of sustained muscle contraction of the intercostals and diaphragmatic spasm encouraged and facilitated by rapid, deep respiration.⁷¹

Asymmetric tone between the hemidiaphragms can shift pressure below the hemidiaphragms, shift abdominal viscera, reduce effectiveness of rib cage muscles, and reduce trunk flexibility or ability to rotate and diminish ventilation, thereby placing greater demand on anterior cervical accessory respiratory muscle. For example, weakness of the obliques, accompanied by contraction of the single right hemidiaphragm, would displace the right abdominal contents caudad, driving the abdominal viscera cephalad on the left, thereby pushing the viscera against the left lung and mediastinum.⁵⁰ Displacement of the mediastinum would, in turn, in this case, compress the right lung. A patient with this asymmetry can be expected to reduce pleural pressure during inspiration more on the side with the intact diaphragm than on the other side. This would result in transmediastinal pressures, which drive the mediastinum toward the side with the intact diaphragm.⁵⁰ This kind of displacement decreases the mechanical efficiency of the intact diaphragm in expanding the lung on that side; part of the diaphragmatic volume displacement is wasted in the mediastinal displacement. This results in counterclockwise rotation of the thoracoabdominal contents and equal volume displacements of the mediastinum and hemidiaphragm with no change in lung volume and no changes in pressure.⁴⁹⁻⁵¹ Greater inspiratory efforts through the cervical accessory muscle are needed because of this rotation of the abdominal viscera; mediastinal shifting; and shortening, lowering, and flattening of the diaphragm. The diaphragm begins to take on a more postural mechanical role because the resultant shorter operational length of the diaphragm reduces its maximal tension in respiration, and static diaphragmatic tension complements the increased demand placed on the parallel paravertebral muscle fiber of the back.

Static overcontraction of the diaphragm also changes the rib cage dimension and anatomic arrangement of the ribs. The osseous relationship of the ribs to the vertebrae influences external or outward rotation of the ribs as the diaphragm contracts.^{31, 67} As a result of ongoing external rotation of the mid to lower thoracic ribs, secondary to diaphragmatic or hemidiaphragmatic hypertonicity, the normal kyphosis of the thoracic spine is reduced, the posterior mediastinum is lengthened or stretched, and the midthoracic spine becomes flatter. Compensatory increase of lumbar lordosis and posterior rotation of the cranium also become inevitable.

Lastly, a more tightly curved diaphragm with a smaller radius results in a more effective conversion of tangential tension to transdiaphragmatic pressure. The more flat the diaphragm or hemidiaphragm becomes as a result of hypertonicity or oblique weakness, the less effective the tangential tension and thus the lower the transdiaphragmatic pressure.^{37, 66} This translates into increased ventilatory demand on the cervical anterior accessory muscle and fascia. Therefore, to maximize tangential tension and transdiaphragmatic pressure, it is necessary to impede diaphragm shortening by contracting the abdominal muscles and keeping the rib cage size constant.²⁵

Coordination and Timing of Respiratory Muscle

Normally, when one breathes strenuously against high inspiratory or expiratory resistances, paradoxical motion of the chest and abdomen can be observed. Asynchronous breathing usually is not the result of poorly coordinated action of respiratory muscles but probably the result of an ineffective, low, flat diaphragm.¹ Therefore, before one can be successful in improving sequential, timed respiration, reestablishment of appropriate diaphragmatic position and length needs to be addressed.

Alterations in the timing of contractions between the diaphragm, other inspiratory muscles, and the obliques may result in synchronous or dyssynchronous thoracoabdominal movement. Dyssynchrony of the rib cage and abdomen may also occur when the intensity of contraction differs from one muscle group to the other. Therefore, coordinated muscle timing and intensity of contraction, which is related to muscle tone properties, can have an impact on respiratory efficiency, endurance, and physiologic activities. There is evidence that shows dyssynchrony of the respiratory muscles in some patients with severe chronic airway obstruction during unsupported arm work.^{3,9} It appears that some of the muscles of the upper torso partake in activities other than breathing, which results in competing ventilatory and nonventilatory work with resultant development of dyssynchrony.³

Respiratory muscles possess no intrinsic contractile mechanism. The breathing cycle is regulated by a complex system of organized neurons.^{12, 32} The respiratory muscles are innervated by a wide distribution of motor neurons from the sternocleidomastoids (cranial nerve XI) to the abdominal muscles (L1). Automatic and voluntary pathways are all different; however, the respiratory and tonic functions of some of these muscles are integrated at the spinal level.⁵⁵ The complexity of this rhythmic autonomous breathing system continues in that some of the respiratory muscles participate in other physiologic activities, such as maintenance of posture, speech, defecation, and parturition. Therefore, to perform one or more of these functions and continue to breathe, it is necessary to maintain a high degree of coordination, timing, and tonic balance.²³

Respiratory alterans consists of an alternation of predominantly thoracic and predominantly abdominal respiratory movements. This phenomenon represents an alternating process of fatigue and recovery between the diaphragm and the rib cage muscles.²⁹ Alternating paradoxical movement represents a condition of respiratory muscle weakness or fatigue in which an attempt is made by the patient to shift the load among various muscle groups. During unresponsive arm exercise, the patient loses effective use of respiratory muscles attached to the upper shoulder girdle.¹⁰

On careful visual observation of the neck and abdomen, one can distinguish abdominal muscle compensation from diaphragmatic weakness. It is characterized by contraction of the external oblique muscles during expiration in the upright position, thus raising the diaphragm dome into the rib cage. Then the abdominal muscles relax and the diaphragm descends during inspiration. Abdominal muscles and gravity are used by the patient to pump the diaphragm in its normal direction.

Abdominal muscle compensation of respiratory alterans is different from rib cage paradox. Patients with weak rib cage musculature, secondary to trauma or thoracic outlet surgery, do not have the respiratory muscles of the upper thorax and neck to stabilize the rib cage. When the diaphragm contracts, it generates a more negative pleural pressure as the lungs expand, which tends to

collapse the rib cage. *Rib cage paradox* reflects rib cage movement in the wrong direction during inspiration.¹¹

Passive Properties of the Thorax

Low chest wall compliance has been shown to influence patients who breathe in paradoxical patterns of rapid, shallow respiration.⁶⁹ These patients theoretically would have been expected to breathe slowly and deeply. Passive chest wall stiffening, however, increases respiratory work and contributes to respiratory disability. There are no studies to date that reflect the relationship or influence of decreased chest wall flexibility on asthma, emphysema, or forward head posturing (Hoover's sign).

The volume-pressure curve of the thorax in normal humans is such that its unstressed or neutral volume is found between 60% and 70% of the total lung capacity.⁶⁵ If this volume-pressure curve falls below neutral volume, the elastic recoil force exerted by the passive chest wall is directed outward then has an inspiratory effect. Above this neutral volume, the thorax's elastic recoil is inwardly directed and thus has an expiratory effect.⁶⁵

Individuals who have a hyperinflated thorax and whose functional residual capacity is well above their total lung capacity require recruitment of inspiratory muscle. Because the elastic recoil force of the thorax is inwardly directed, the inspiratory muscles must work against the elastic recoil of both the chest wall and the lungs, rather than just the recoil of the lungs alone. The inspiratory muscles are no longer assisted by the elastic recoil of the chest but must work against it. Functional residual capacity is determined by the static equilibrium between the elastic recoil forces of the lungs and of the chest wall, which are equal in magnitude. In the hyperinflated chest, the increased volume cannot be maintained by this normal mechanism but must be maintained by airway collapse or by inspiratory muscle recruitment or *tonic activity* at end expiration.^{47, 56, 65}

RESPIRATORY DYSFUNCTION IN RELATION TO POSTURAL IMBALANCE

Hyperinflation, dyspnea, and hypercapnea or inspiratory fatigue are the most common respiratory dysfunctional problems seen in patients experiencing temporomandibular dysfunction and associated pain. Reviewing these disorders helps clinicians better understand their relationship to cervical, cranial, and mandibular function and, therefore, appropriate treatment.

Hyperinflation

Hyperinflation occurs frequently in the presence of airway obstruction (asthmatics) and through the loss of elastic recoil by the lung (chronic smokers). Hyperinflation, owing to the shortening fiber length of inspiratory muscle, decreases the force available or the pressure developed for any given level of excitation.⁶³ Therefore, a given pressure swing necessary for an adequate alveolar ventilation requires greater excitation and a greater percentage of the maximum pressure available.^{30, 45} This increases energy consumption for a given workload,

decreases efficiency, and places additional demand on the cervical accessory respiratory muscles.

Tonic contraction of the intercostal and accessory muscles is an important determinant of end-expiratory lung volume in both asthmatics and nonasthmatics.^{46, 47, 57} During hyperinflation, the tonic force of the intercostal and accessory muscles increases. These muscles remain contracted throughout the respiratory cycle, which further increases energy demands and work while efficiency decreases. This persistent, ongoing contraction of the inspiratory muscles throughout the respiratory cycle adversely affects their own blood flow, fatigue level, and efficiency.⁶³ Sustained contraction of the intercostal and accessory muscles also results in a decrease in energy supply. The diaphragm flattens, the axial direction of the fibers decreases, and the area of apposition becomes smaller as the diaphragmatic fibers are dissected obliquely upward.⁵¹ As the diaphragm progressively loses its ability to expand the rib cage, it begins to have an expiratory action on the rib cage.⁵⁴ As a result of net reduction in the transverse diameter of the rib cage, these patients begin to demonstrate Hoover's signs.¹⁵ These patients compensate by lifting or pulling the anterior chest wall with cervical muscles through *pump handle* motion and rib cage expansion. Overuse of the scalene, platysma, hyoid, sternocleidomastoid, and inframandibular muscles, while the patient is in the upright position, influences somatognathic development of compensatory patterns and resultant craniofacial pain and headaches.³⁵ These patients lean forward, as they develop posteriorly rotated craniums, so that they can breathe more easily. Therefore, hyperinflation may place both the diaphragm and the other inspiratory muscles at a threatening mechanical disadvantage because of this geometrical alteration and these compensatory relationships. Table 2 summarizes this discussion.

Dyspnea

Dyspnea, the distressful sensation of uncomfortable breathing, increases with an increase in inspiratory muscle resistance and with a reduction in maxi-

Table 2. SUMMARY OF HYPERINFLATION RELATIONSHIPS

Decreased elastic lung recoil
Shortened length of inspiratory muscle
Decreased inspiratory force
Increased need for inspiratory muscle neural excitement
Increased inspiratory muscle energy consumption
Decreased diaphragm efficiency
Increased cervical accessory respiratory demand
Increased ongoing tonic activity of intercostal and accessory muscle
Increased energy demands and respiratory fatigue
Decreased circulatory blood flow to inspiratory muscle (hypoxemia)
Decreased cephalocaudal diaphragmatic muscle fiber orientation (flattened diaphragm)
Increased expiratory action of the diaphragm (upon contraction, the diaphragm pulls the costal margins together without lowering its dome and without producing a transdiaphragmatic pressure difference)
Decreased area of apposition
Increased pull on cervical extensors, rotators, and accessory respiratory muscles
Increased Hoover's sign and forward head posture

mal force produced by the inspirational muscles.^{4, 33} In the maintenance of large and fatiguing resistance loads, the contribution of these muscles to the ventilatory effort varies over time, in that as the diaphragm decreases activity, sternocleidomastoid recruitment increases.^{4, 62} The diaphragm may lack the sensory receptors necessary to mediate the sensation of dyspnea. The diaphragm is poorly supplied with muscle spindles and afferent receptors, which some have hypothesized to mediate the sensation of dyspnea.^{2, 7, 17} A shift in ventilatory work from the rib cage and accessory muscles to the diaphragm with voluntary diaphragmatic breathing may reduce the sensation of dyspnea.⁴

Those who do not practice diaphragmatic breathing exercises alter their body position, so that the diaphragm is enabled to assume a greater portion of the muscular work of breathing. This relieves the inspiratory accessory muscles of the task. Proprioceptive impulses from the accessory muscles reduce, which leads to reduction in the sensation of dyspnea. Postural relief of dyspnea is correlated with reduction or cessation of accessory muscle activity.²

Dyspnea or shortness of breath leads to the development of a forward head posture with the encouragement of posterior cranial rotation. This position reverses the suboccipital kyphosis into a lordosis producing approximation of the occiput to the atlas and axis. Suboccipital compression may compromise the trigeminocervical complex.

Normal shoulder girdle posture cannot continue in the presence of a prolonged forward head posture. As the occiput approximates the shoulder girdle, shortening of the upper trapezius and levator scapulae occurs. Forward migration and internal rotation of the glenohumeral joint and compression of the sternoclavicular and acromioclavicular joints with concomitant shortening of the pectorals can all be attributed to influence of dyspnea. Cumulative factors leading to shoulder impingement, temporomandibular loading, and neurovascular compression syndromes exist.

Headaches relating to dyspnea originate usually in the occipital vertex, retroorbital, and temporal regions because of irritation of the greater occipital nerve, which courses through the semispinalis capitis and occipital attachment of the upper trapezius muscle. Pain referred from the upper trapezius to the temporal arch may produce contraction of the temporalis muscle, a primary elevator of the mandible.

TREATMENT CONSIDERATIONS

In reviewing the literature, this clinician found no difficulty in finding information on improving diaphragmatic contractility through the use of drugs and restoring the balance between energy supply and demands by treating hypoxemia, improving cardiac output, and by treating bronchospasm or pulmonary edema. General fundamental approaches were used in training individuals to improve respiratory strength or endurance or both. Ventilatory muscle strength has been increased in normal subjects by having them perform maximum static inspiratory and expiratory pressure maneuvers repeatedly³⁹ and in quadriplegic patients by having them breathe through resistances.²⁸ It is likely that an increase in respiratory muscle strength provides sufficient reserve to overcome a sudden increase of respiratory load and improves endurance by decreasing the function of maximum pressure required to breathe⁶³; however, it does not necessarily improve length-to-tension ratios, diaphragmatic alignment, zone of apposition, or antagonistic-agonistic tone.

Few authors recognize the importance of balancing the respiratory system

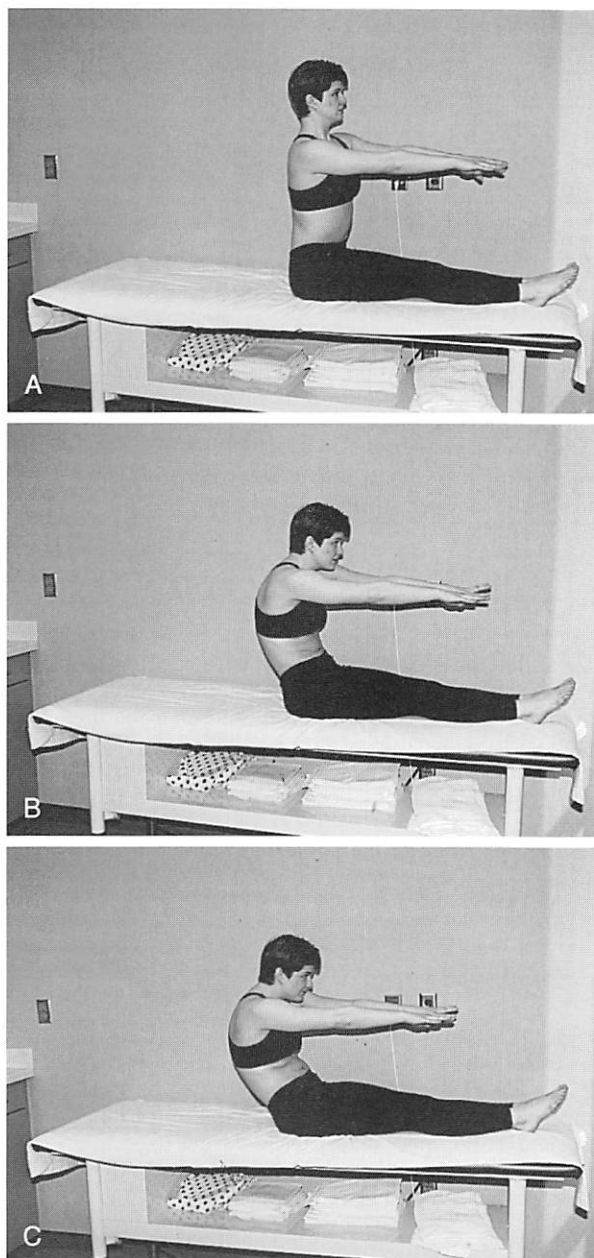


Figure 1. A–F, Reverse curl downs. With knees straight in a long seated position, breathe in through the nose. Lower the back to the firm surface slowly, while curling the back, reaching with extended arms and blowing slowly through curled lips. The low back will touch the surface first, followed by midback and then the head. Inhale through the nose. Turn to one side and blow out again as the trunk curls up. Repeat eight times, alternating curl ups from one side to the other.

Illustration continued on opposite page

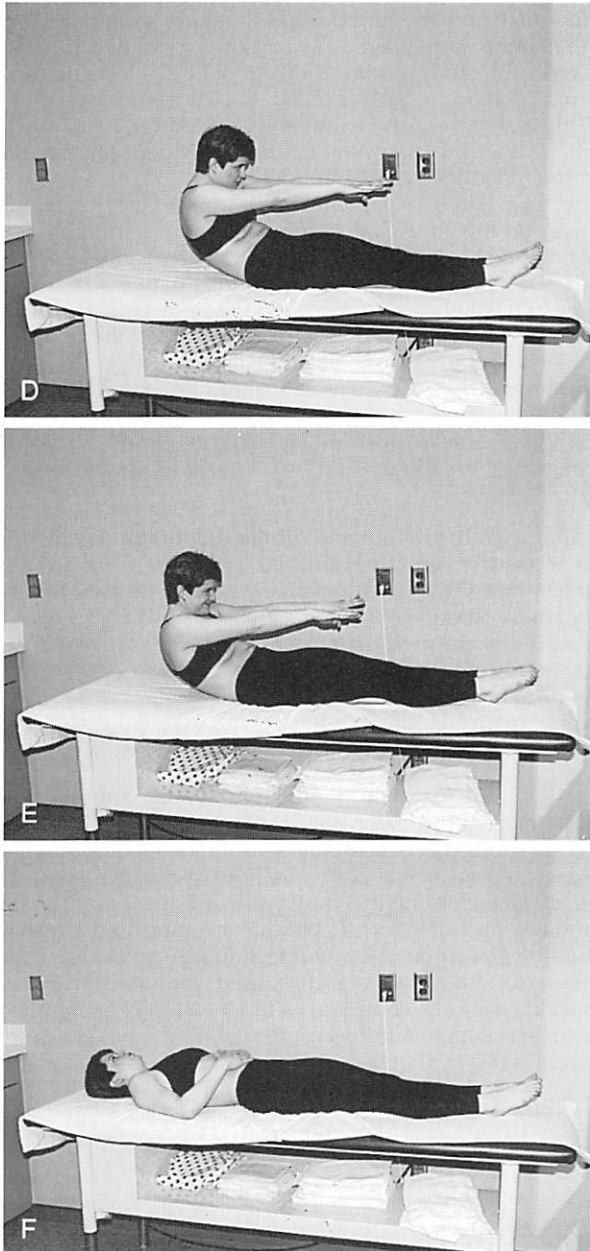


Figure 1 (Continued).

through diaphragmatic breathing techniques that are simultaneously carried out during specific oblique strengthening exercises. In addition to concerns regarding lack of respect for the importance of the oblique strengthening, the author found scanty information on polyarticular muscle chain influence on torsional and rotational dysfunction of the trunk and thus on the head and neck. In fact, only one article reviews the important relationships between the diaphragm and the psoas and the mandible and the abdomen.⁵

Specifically, one needs to remember the importance of strengthening the internal obliques and the gluteals to help maintain proper diaphragmatic length-tension tone and zone of apposition. Rotation of the trunk needs to be secured equally to both directions so that dyssynchronous patterns of respiration can be minimized, and inflexibility and asymmetric tone of both the postural and the respiratory muscles can be avoided. Stretching regularly the pectorals, latissimus dorsi, shoulder internal rotators, and hip flexors assists in decreasing rotary restriction patterns and possible scoliosis. Coordination and timing of respiratory muscle, passive and active properties of the thorax, and respiratory dysfunctional patterns in relation to postural imbalances would all improve through specific diaphragmatic breathing exercises. Emphasis should also be placed on the following:

1. Pause after each breath out and let the diaphragm set the breathing rate, not the accessory respiratory muscle.
2. Remember that the exhalation phase should be two times longer than the inhalation phase.
3. Inhale regularly through the nose.
4. Exhale periodically through curled lips.
5. Breathe once every 5 to 6 seconds.
6. Wear unrestrictive clothing.
7. Keep the head up and between the shoulders, not in front of them.

To help restore and maintain hemidiaphragmatic alignment, reverse curl-downs should be carried out daily (Fig. 1). To help dyspnea in the early stages of treatment and before the development of good oblique strength and trunk control, consider the use of an abdominal-oblique corset, with elastic wrap-around straps that can be angled down toward the pubis to help maintain abdominal pressure and assist with oblique position and awareness. Finally, emphasis should be placed on relaxation techniques and tools; walking; shifting weight from side to side when standing; and prolonged exhalation through whistling, humming, singing, counting, or talking slowly using phonetic emphasis. Asthmatics need to maintain nasal passage, and smokers need to consider cessation before assuming that any intervention will be successful in treating TMD.

SUMMARY

This article reviewed the anatomic issues of respiration and the active and passive mechanics of the thorax as related to dysfunctional breathing. Influences from respiratory dysfunction on forward head posture and temporomandibular dysfunction were offered. Discussion of inspiratory and expiratory muscle responsibilities, effects of diaphragmatic dystonia and abdominal weakness, and results of improper coordination and timing of respiratory muscle should all give the dentist and physical therapist an appreciation of the need for careful

observation and appropriate treatment with the patient experiencing TMD and dysfunctional respiratory mechanics. Summaries of hyperinflation relationships and treatment considerations should help in the management of TMD.

References

1. Ashutosh K, Gilbert R, Auchincloss JH, et al: Asynchronous breathing movements in patients with obstructive pulmonary disease. *Chest* 67:5, 1975
2. Baroch AL: Chronic obstructive lung disease: Postural relief of dyspnea. *Arch Phys Med Rehabil* 55:2, 1974
3. Bartolome RC: Clinical and physiologic evaluation of respiratory muscle function. *Clin Chest Med* 10:2, 1989
4. Breslin EH, Garoutte BC, Kohlman V, et al: Correlations between dyspnea, diaphragm and sternomastoid recruitment during inspiratory resistance breathing in normal subjects. *Chest* 98:1, 1990
5. Buchholz I: Breathing, voice, and movement therapy: Applications to breathing disorders. *Biofeedback Self Regul* 19:2, 1994
6. Campbell EJ, Agostoni E, Newsom-Davis J: The respiratory muscles: Mechanics and neural control. London, Lloyd-Lake, 1970
7. Campbell EJ, Howell JB: The sensation of breathlessness. *Br Med Bull* 19:36, 1963
8. Celli BR: Arm exercise and ventilation. *Chest* 93:6, 1988
9. Celli BR, Rassulo J, Corral R: Ventilatory muscle dysfunction in patients with bilateral diaphragmatic paralysis: Reversed by external negative pressure ventilation. *Am Rev Respir Dis* 136:11, 1987
10. Celli BR, Rassulo J, Make B: Dyssynchronous breathing associated with arm but not leg exercise in patients with chronic obstructive pulmonary disease. *N Engl J Med* 314:1485, 1986
11. Clanton TL, Diaz PT: Clinical assessment of the respiratory muscles. *Phys Ther* 75:11, 1995
12. Cohen MI: Central determinants of respiratory rhythm. *Am Rev Physiol* 43:1, 1981
13. Criner G, Celli BR: Ventilatory muscle recruitment in exercise with O₂ in obstructed patients with mild hypoxemia. *J Appl Physiol* 63:1, 1987
14. Danon J, Diaz WS, Goldberg NB, et al: Function of the isolated pored diaphragm and the cervical accessory muscles in CT quadriplegics. *Am Rev Respir Dis* 119:909-919, 1979
15. DeTroyer A: Respiratory muscle function in chronic obstructive pulmonary disease. In Casaburi R, Petty L (eds): *Principles and Practice of Pulmonary Rehabilitation*. Philadelphia, WB Saunders, 1993
16. DeTroyer A, Estenne M: Coordination between rib cage muscles and diaphragm during quiet breathing in humans. *J Appl Physiol* 57:899, 1984
17. DeTroyer A, Estenne M: Functional anatomy of the respiratory muscles. *Clin Chest Med* 9:2, 1989
18. DeTroyer A, Estenne M: Functional anatomy of the respiratory muscles. In Belmen MJ (ed): *Respiratory Muscles: Function in Health and Disease*. Philadelphia, WB Saunders, 1985, pp 175-195
19. DeTroyer A, Kelly S, Zin WA: Mechanical action of the intercostal muscle on the ribs. *Science* 120:1, 1983
20. DeTroyer A, Sampsom M, Sigrist S, et al: The diaphragm: Two muscles. *Science* 213:237-238, 1981
21. Druz WS, Sharp TJ: Activity of respiratory muscles in upright and recumbent lumbers. *J Appl Physiol* 51:4, 1981
22. Duron B: Intercostal and diaphragmatic muscle ending and afferents. In Horblin TF (ed): *Regulation of Breathing*. New York, Marcel Dekker, 1981, pp 473-527
23. Euler Von C: On the central pattern generator for the basic breathing rhythmicity. *J Appl Physiol* 55:4, 1983
24. Farkas GA, Decramer M, Rochester DF, et al: Contractile properties of intercostal muscles and their functional significance. *J Appl Physiol* 59:2, 1985

25. Fitting JW, Grassino A: Diagnosis of diaphragmatic dysfunction. *Clin Chest Med* 8:1, 1987
26. Goldman M, Mead J: Mechanical interaction between the diaphragm and the rib cage. *J Appl Physiol* 35:2, 1973
27. Grimby G, Broom J, Mead J: Relative contribution of rib cage and abdomen to ventilation during exercise. *J Appl Physiol* 24:1, 1968
28. Gross D, Ladd HW, Riley EJ, et al: The effect of training on strength and endurance of the diaphragm in quadriplegia. *Am J Med* 68:1, 1980
29. Grossino A, Bellemore F: Respiratory muscle fatigue and its effects on the breathing cycle. *In* Von Euler C, Lagerantz H (eds): *Central Nervous Control Mechanisms in Breathing*. Elmsford, NY, Pergamon, 1979, pp 465-472
30. Grossino A, Goldman MD, Mead J, et al: Mechanics of the human diaphragm during voluntary contractions: dynamics. *J Appl Physiol* 44:2, 1978
31. Hruska RJ: Postural Reconstruction: An Integrated Approach to Treatment of Upper Half Musculoskeletal and Respiratory Dysfunction. Instructional lab courses, Lincoln, NE, 1995
32. Kelsen SG, Cherniak NS, Mannes Y: Central control of respiratory muscle activity. *In* Roussos C, Macklem PT (eds): *The Thorax*. New York, Marcel Dekker, 1985, pp 493-529
33. Killian KJ, Gandevia SC, Summers E, et al: Effect of increased lung volume on perception of breathlessness, effort, and tension. *J Appl Physiol* 57:2, 1984
34. Konno K, Mead J: Measurement of the separate volume changes of rib cage and abdomen during breathing. *J Appl Physiol* 22:2, 1967
35. Kraus SL: Cervical spine influences on the craniomandibular region. *In* Kraus SL (ed): *TMJ Disorders: Management of the Craniomandibular Complex*. New York, Churchill Livingstone, 1988
36. Langman J: Medical Embryology. Baltimore, Williams & Wilkins, 1978, p 305
37. Laporta D, Grassino A: Assessment of transdiaphragmatic pressure in humans. *J Appl Physiol* 58:4, 1985
38. Leak LV: Gross and ultrastructural morphologic features of the diaphragm. *Am Rev Respir Dis* 119:1, 1979
39. Leith DE, Bradley M: Ventilatory muscle strength and endurance training. *J Appl Physiol* 41:2, 1978
40. Loring SH, DeTroyer A: Actions of the respiratory muscles. *In* Roussos C, Macklem PT (eds): *The Thorax*. New York, Marcel Dekker, 1985, pp 327-349
41. Loring SH, Mead J: Action of the diaphragm on the rib cage inferred from a force-balance analysis. *J Appl Physiol* 53:2, 1982
42. Mannheimer JS, Attanasio R, Cinotti WR, et al: Cervical strain and mandibular whip-lash: Effects upon the craniomandibular apparatus. *Clin Prev Dent* 11:29, 1989
43. Mannheimer JS, Dunn J: The cervical spine, its evaluation and relation to the temporomandibular joint. *In* Kaplan A (ed): *Textbook of Craniomandibular Disorders*. Philadelphia, WB Saunders, 1991
44. Mannheimer JS, Rosenthal RM: Acute and chronic postural abnormalities as related to craniofacial pain and temporomandibular disorder. *Dent Clin North Am* 35:1, 1991
45. Marshall R: Relationship between stimulus and work of breathing at different lung volumes. *J Appl Physiol* 17:2, 1962
46. Martin JG, Habib M, Engel LA: Inspiratory muscle activity during induced hyperinflation. *Respir Physiol* 39:3, 1980
47. Martin JG, Powell E, Shore S, et al: The role of respiratory muscles in the hyperinflation of bronchial asthma. *Am Rev Respir Dis* 121:13, 1980
48. Maskill D, Murphy K, Mier A, et al: Motor cortical representation of the diaphragm in man. *J Phys Great Britain* 443:119, 1991
49. McCool FD, Loring SH, Mead J: Rib cage distortion during voluntary and involuntary breathing acts. *J Appl Physiol* 58:4, 1985
50. McCool FD, Tzelepis GE, Mead J: Absence of a hemidiaphragm: Mechanical implications. *Lung* 169:1, 1991
51. Mead J: Functional significance of the area of apposition of diaphragm to rib cage. *Am Rev Respir Dis* 11:31, 1979
52. Mead J, Loring SH: Analysis of volume displacement and length changes of the diaphragm during breathing. *J Appl Physiol* 53:1, 1982

53. Mier A, Brophy L, Estenne M, et al: Action of the abdominal muscles on the rib cage in humans. *J Appl Physiol* 58:4, 1985
54. Minh V-D, Dolan GF, Konopka RF: Effect of hyperinflation on inspiratory function of the diaphragm. *J Appl Physiol* 40:1, 1976
55. Moltke E, Skouby AP: The influence of tonic neck reflexes on the activity of some muscles of the trunk in patients with asthma and emphysema. *Acta Med Scand* 173:3, 1963
56. Muller NL, Bryan AC, Zamel N: Tonic inspiratory muscle activity as a cause of hyperventilation in asthma. *Am Rev Respir Dis* 121:171, 1980
57. Muller NL, Bryan AC, Zamel N: Tonic inspiratory muscle activity as a cause of hyperinflation in histamine-induced asthma. *J Appl Physiol* 49:2, 1981
58. Rahn HO, Otis AB, Chadwick LE, et al: The pressure-volume diagram of the thorax and lungs. *Am J Physiol* 146:2, 1946
59. Reddy V, Shauma S, Cobanoglu A: What dictates the position of the diaphragm—the heart or the liver? *J Thorac Cardiovasc Surg* 108:4, 1994
60. Reid WD, Dechman G: Considerations when testing and training the respiratory muscles. *Phys Ther* 75:11, 1995
61. Road JD, Lervers AM, Goldman E, et al: Respiratory muscle coordination and diaphragm length during expiratory threshold loading. *J Appl Physiol* 70:4, 1991
62. Roussos CH, Fixley M, Gross D, et al: Fatigue of the inspiratory muscles and their synergistic behavior. *J Appl Physiol* 46:2, 1979.
63. Roussos CH, Macklem PT: The respiratory muscles. *N Engl J Med* 307:13, 1982
64. Sant Ambrogio G, Frazier DT, Wilson MF, et al: Motor innervation and pattern of activity of cat diaphragm. *J Appl Physiol* 18:1, 1963
65. Sharp JT: The chest wall and respiratory muscles in airflow limitation. *In* Roussos C, Macklem PT (eds): *The Thorax*. New York, Marcel Dekker, 1985
66. Sharp JT: The respiratory muscles in emphysema. *Clin Chest Med* 4:4, 1993
67. Sharp JT, Beard GA, Sungo M, et al: The rib cage in normal and emphysematous subjects: A roentgenographic approach. *J Appl Physiol* 61:4, 1986
68. Sharp JT, Goldberg NB, Drux WS, et al: Relative contributions of rib cage and abdomen to breathing in normal subjects. *J Appl Physiol* 39:2, 1974
69. Ting EY, Lyons HA: Pressure-volume relations of lung and thoracic cage in pulmonary emphysema. *J Appl Physiol* 16:2, 1961
70. Urbanowiz M: Alteration of vertical dimension and its effect on head and neck posture. *J Craniomandib Pract* 9:2, 1991
71. Wolf SG: Diaphragmatic spasm: A neglected cause of dyspnoea and chest pain. *Integ Physical Behav Sci* 29:1, 1994

Address reprint requests to

Ronald J. Hruska, Jr, MPA, PT
 Department of Physical Therapy
 St. Elizabeth Community Health Center
 555 South 70th Street
 Lincoln, NE 68510